CHAPTER

17 Paediatric surgery

Learning objectives

After studying this chapter, you will be able to:

- Outline subspecialisations within children's surgery
- Safely prescribe perioperative fluids in children
- Compare and contrast inguinal hernias and hydroceles
- Discuss the causes and management of the acute scrotum
- Outline the presentation, resuscitation and operation for pyloric stenosis
- Outline causes and management of abdominal pain in children of different ages
- Describe two solid abdominal tumours of childhood

INTRODUCTION

In high-income countries paediatric surgeons have subspecialised, whereas in low-income countries surgeons must maintain diverse skills and knowledge. Some conditions, previously managed by paediatric surgeons, are now managed by others (e.g. clefts in plastic surgery, syndactyly in hand surgery, spina bifida and ventriculoperitoneal shunts in neurosurgery, ligation of patent ductus arteriosus in cardiac surgery and cervical cystic hygromas, thyroglossal cysts, preauricular sinuses and branchial remnants in ear, nose and throat surgery). This new edition recognises specialisation with chapters devoted to neonatal surgery, specialist paediatric urology and paediatric trauma. Those managing the general surgery of childhood in non-specialist hospitals should study the inguinoscrotal conditions described here and the foreskin as outlined in *Chapter 20*.

AGE

Biological domains (e.g. physiology, pathology, pharmacology) change continuously with age, whereas hospital services recognise artificial boundaries often set at 12, 16 or 18. The terminology related to children and young people (CYP) includes **neonate** (<4 weeks) and **infant** (<1 year). The World Health Organization defines **adolescence** as ages 10–19 and **young people** as 10–24. Some anatomical differences between infants and older children appear in *Table 17.1* and *Figure 17.1*. A few conditions described in *Chapter 18* require management throughout childhood and later after handover in transitioning by adult surgeons.

ENVIRONMENT

Children, especially infants, should be managed in a warm environment. Compared with adults, children lose more heat and fluid with surface area to weight ratios being higher;

TABLE 17.1 Some examples of differences between infants and older children

Facts	Infants and some young children have a wide abdomen, a broad costal margin and a shallow pelvis
	The edge of the liver comes below the costal margin, and the bladder is partly intra-abdominal
	The ribs are more horizontal and are flexible
	The umbilicus is relatively low lying
Implications	Transverse supraumbilical incisions can give greater access than vertical midline incisions
	Abdominal trauma (including surgical incisions) can easily damage the liver or bladder
	The geometry of the ribs means that ventilation requires more diaphragmatic movement than in adults
	A stoma in the lower abdomen of an infant must be carefully sited for its bag not to interfere with the umbilicus

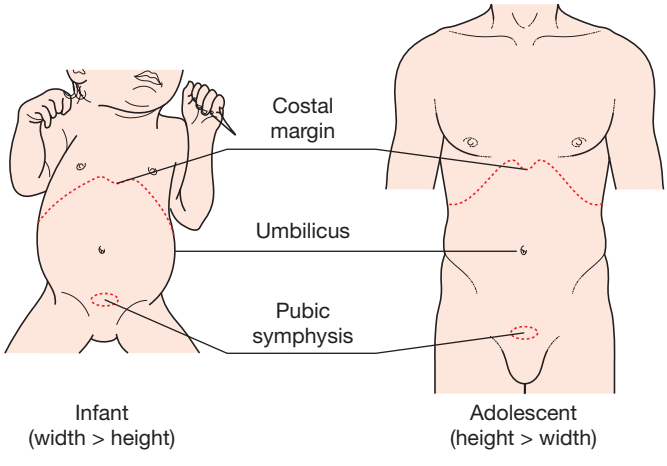

Figure 17.1 Topographical differences in the abdomen.

consider this in the clinic, emergency room, anaesthetic rooms and theatres. An infant's head accounts for 20% of the surface area compared with 10% in adults. Intravenous infusions are warmed, and respiratory gases are both warmed and humidified. Core temperature is monitored in operations, and warming devices are used (e.g. heated mattresses, warm air blowers).

PERIOPERATIVE FLUIDS

There are four reasons for giving intravenous fluids: acute circulatory support, correction of previous losses, replacing ongoing losses and maintenance fluids (***Summary box 17.1***). Before prescribing fluids, weight, vital signs and fluid requirements are considered (***Table 17.2***). Dehydration as a percentage loss of total body water is difficult to assess; moderate dehydration (5%) causes low urine output, dry mouth and sunken eyes and fontanelle; severe dehydration (>10%) causes drowsiness, tachycardia and slow capillary refill (>2 seconds).

Hyponatraemia (<135 mmol/L) is common, but progression risks an encephalopathy from water movement into the brain. Water diffuses slowly by osmosis, equalising osmotic pressures, or swiftly through aquaporins. Sodium homeostasis maintains intravascular volume through antidiuretic hormone (ADH) and thirst. ADH binds to receptors in the distal nephron, inducing aquaporins and water retention. Increasing plasma osmolarity and hypotension both increase ADH levels.

Summary box 17.1

Fluids in children

Fluids are given intravenously for four reasons:

- Circulatory support in resuscitating vascular collapse
  - 0.9% saline, Blood, 4.5% albumin, Colloid — Given as a bolus of 10 or 20 mL/kg over periods of up to 20 minutes while monitoring the response. Can be repeated up to 40 mL/kg then seek help
- Replacement of previous fluid and electrolyte deficits
  - 0.9% saline 0.15% KCl, Hartmann's solution — Given over a longer period of up to 48 hours with clinical and biochemical review
- Replacement of ongoing losses
  - 0.9% saline + 0.15% KCl, Hartmann's solution — Or a fluid tailored to the losses, e.g. 4.5% albumin if protein loss is great. Replace losses millilitre for millilitre
- Maintenance outside the neonatal period
  - Plasma-Lyte 148, Hartmann's solution ± glucose, 0.9% saline + 0.15% KCl ± glucose — Hypotonic 0.18% saline should not be used outside the neonatal period

TABLE 17.2 Basic paediatric data.

Vital signs			
Age (years)	Heart rate (bpm)	Systolic blood pressure (mmHg)	Respiratory rate (b/min)
<1	110–160	70–90	30–40
2–5	90–140	80–100	25–30
5–12	80–120	90–110	20–25
Maintenance fluid requirements			
Weight		Daily fluid requirement (mL/kg/day)	(mL/kg/h)
Neonate		120–150	5
First 10 kg		100	4
Second 10 kg		50	2
Subsequent kg		20	1

Systolic blood pressure = 80 + (age in years × 2) mmHg
Circulating blood volume = 70–80 mL/kg (90–100 mL/kg in preterms)
b/min, breaths per minute; bpm, beats per minute.

An abundance of free water causes hyponatraemia. Since glucose is metabolised to water, glucose is ignored when calculating tonicity; 0.45% saline in 5% dextrose is considered hypotonic. Hyponatraemia is seen in normovolaemia if ADH rises inappropriately (e.g. surgical stress, trauma, chest infections, head injuries). Clinical problems arise if hypotonic fluids are used to resuscitate or replace losses or if maintenance fluids are given in excess.

Restricting maintenance fluids to 50–70% is appropriate after major surgery, gradually increasing the rate daily if sodium levels are not falling. Urine output naturally decreases after major surgery, but a common pitfall is to increase maintenance fluids, predisposing to hyponatraemia. A postoperative fluid bolus is appropriate in hypovolaemia, hypotension or poor peripheral perfusion, but given simply because urine output is low can be inappropriate. If hyponatraemia is mild and asymptomatic fluids are restricted, if symptomatic with headache, lethargy or seizures and the sodium concentration is <125 mmol/L, intravenous 3% saline is given.

HISTORY AND EXAMINATION

An opportunistic rather than a systematic approach may be needed in the preschool child. Children should be told what to expect from examinations, investigations or procedures in terms they can understand. Fear, anxiety and pain are reduced in a child-friendly environment. Consent is requested from someone with parental responsibility.

OPERATIVE SURGERY

Preoperative fasting should be limited (***Summary box 17.2***). Surgery requires meticulous and gentle tissue handling, strict haemostasis, fine sutures and magnification. Tissues should

Alexis Frank Hartmann, 1898–1964, paediatrician, St Louis, MO, USA, described the solution; should not be confused with Henri Albert Charles Antoine Hartmann, French surgeon, who described the operation that goes by his name.

be well vascularised, tension avoided and contamination minimised. The intestine can be anastomosed with single-layer interrupted or continuous extramucosal sutures. Wounds are closed with absorbable sutures in layers or a mass closure. Establishing a layer of fat between skin and muscle in the malnourished or thin child prevents the skin from adhering to muscle. Toothed forceps may be used when closing the skin, but the skin must not be punctured; epidermal tunnels can form, trapping skin debris and creating a comedo-like blackhead. Clean skin incisions are closed with absorbable subcuticular sutures or skin glue, avoiding staples. Minimally invasive approaches can be used at all ages with appropriate instruments, flow rates and pressures. Postoperatively, children recover swiftly with adequate analgesia.

Summary box 17.2

Fasting instructions

- 1 hour for clear fluids
- 4 hours for breast milk
- 6 hours for solids

INGUINOSCROTAL DISORDERS

Undifferentiated gonads, influenced by the Y chromosome, develop into testes in the posterior abdominal urogenital ridges. An abdominal phase in testicular descent involves migration towards the internal ring guided by the gubernaculum. Descent into the scrotum requires fetal testicular testosterone. The peritoneum preceding the testis through the inguinal canal becomes the processus vaginalis, which usually obliterates after birth; failure of obliteration leads to an indirect inguinal hernia or hydrocele (*Figure 17.2*).

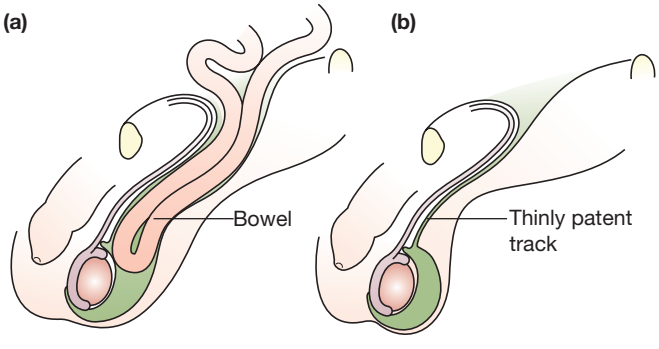

Figure 17.2 (a) Inguinal hernia and **(b)** hydrocele in children are the result of incomplete obliteration of the processus vaginalis.

Inguinal hernias

Inguinal hernias occur in 4% of infants with prematurity, low birth weight and male sex being risk factors (M:F 6:1). Inguinal hernias are twice as common on the right side as on the left, with 10% occurring bilaterally. The hernia may contain omentum, intestine, appendix (Amyand's) or a Meckel's diverticulum (Littre's). An ovary can prolapse and twist in a girl, requiring emergency exploration. Prolapsed ovaries, therefore, need prompt repair. Rarely in phenotypic girls, a testicle is found, suggesting androgen insensitivity (see *Chapter 20*).

An inguinal hernia presents as an intermittent bulge in the groin extending to the scrotum (*Figure 17.3*) or labia, often exacerbated by crying or straining. Most reduce on lying down or with gentle manipulation. A thickened cord in boys, or round ligament in girls, may be all that is palpable. Reducible inguinal hernias are repaired electively. If the herniated contents become firm, tender and irreducible, there may be oedema and erythema, irritability, vomiting and the passage of some rectal blood. An attempt to reduce an incarceration with sustained gentle pressure may be successful; if unsuccessful, emergency exploration, reduction and repair are required.

Inguinal hernia repair

The herniated contents may reduce after the induction of anaesthesia. If incarcerated, the neck of the sac is found at the external ring. Open repair involves ligating the sac at the external or the internal inguinal ring. In a repair at the internal ring, an incision is made over the inguinal canal, Scarpa's fascia is incised and the fat cleared to expose the external oblique rolling over to form the inguinal ligament. The external

Figure 17.3 A left inguinal swelling. Clinical examination is needed to confidently distinguish a hydrocele from an inguinal hernia.

Claudius Amyand, 1660–1740, French surgeon who performed the first successful appendectomy in 1735. He was first Principal Surgeon to the Westminster Hospital, and founder and first Principal Surgeon to St George's Hospital in London.
Johann Frederick Meckel (the Younger), 1781–1833, Professor of Anatomy and Surgery, Halle, Germany, described his diverticulum in 1809.
Alexis Littre, 1654–1726, surgeon and lecturer in anatomy, Paris, France, described Meckel's diverticulum in a hernial sac in 1700, 81 years before Meckel was born.
Antonio Scarpa, 1752–1832, Italian anatomist and pupil of Morgagni.

oblique is incised to identify the cremaster overlying the sac. The cremaster is opened with fine scissors or blunt dissection. The cord is lifted through the cremaster and a clip passed behind. The sac is mobilised from the testicular vessels and vas deferens. The sac is divided, twisted to reduce any contents and transfixed/ligated at the internal ring. The wound is closed in layers. A laparoscopic approach places an encircling suture at the internal ring.

Hydroceles

A hydrocele is a fluid collection between the parietal and visceral layers of the tunica vaginalis and is usually confined to the scrotum – one can feel the cord above it. Occasionally, it extends into the external ring and one cannot feel the cord. Hydroceles are typically asymptomatic, non-tender and may fluctuate, reducing overnight; they can be bilateral. Infant hydroceles can be tense and uncomfortable, especially if over-examined, causing confusion with an incarcerated inguinal hernia. Although hydroceles transilluminate, this is a flawed test for distinguishing one from an incarcerated inguinal hernia since light easily shines through an infant's intestine.

Surgery is rarely indicated before 2 years because a majority resolve. Occasionally an encysted hydrocele of the cord (or hydrocele of the canal of Nuck in a girl) forms as the processus obliterates; persistence warrants exploration. Occasionally, a febrile boy presents with a viral-like illness and an acute hydrocele. These generally resolve over a few weeks, and only those that remain need exploration. Ligation of a patent processus vaginalis is similar to an inguinal hernia repair.

Teenage boys may have a non-communicating hydrocele with fluid arising from the tunica vaginalis; a plication (Lord's procedure) or excision/eversion of the tunica vaginalis (Jaboulay procedure) are needed.

Undescended testes

A normally descended testis reaches the scrotal floor with a good cord length above it and remains there. Testicular descent is usually complete by the 30th week of gestation. At birth, 4% of full-term and 30% of premature boys have an undescended testis (UDT). Boys should be examined at birth and at 6 weeks; if a UDT is found, they should be seen at 3 months since a testis is unlikely to descend after this time. An orchidopexy is then scheduled for between 6 and 12 months. Occasionally a palpable UDT undergoes torsion and presents as a painful lump in the groin with an empty hemi-scrotum.

Clinical examination distinguishes a normal testis from a palpable or an impalpable UDT. A testis cannot be palpated in the canal; it can only be felt when delivered to the superficial pouch, which is also called Denis Browne's pouch (a pocket between Scarpa's fascia and the external oblique fascia at the external ring). Cremasteric activity may draw a testis into the pouch or the canal. Gentle strokes over the canal, directed towards the scrotum, may deliver a normal scrotal or a palpable UDT. Ectopic testes are found beneath the skin of the medial thigh or lower abdomen; they have a long cord, facilitating easy scrotal placement at operation. If hypospadias is seen with bilateral, impalpable UDTs, then a disorder of sexual differentiation is possible and referral indicated (see ***Chapter 20***).

Retractile testes

A retractile testis is palpable in the groin and can be brought into the scrotum but promptly returns to the groin. Retractile testes are common in infants and most eventually settle in the scrotum; follow-up is needed because some permanently ascend and require an orchidopexy.

Ascending testes

Some scrotal testes in infancy are later found in the high scrotum or groin with ascent attributed to insufficient cord growth; a few were retractile in infancy. An orchidopexy is required. An argument exists for screening all boys for ascending testes in late childhood.

Palpable undescended testes

Palpable UDTs require an orchidopexy at between 6 and 12 months. The canal is opened through an external oblique incision. The testis is mobilised on its vas and vessels, and the gubernaculum is usually divided. Any peritoneal outpocketing is ligated and divided at the internal ring, where dissection adds length to the cord. The testis is placed in a subdartos scrotal pouch. Early orchidopexy, placing the testis in a cooler environment, improves spermatogenesis and may reduce the risk of testicular malignancy.

Impalpable undescended testes

Impalpable UDTs are absent, canalicular or abdominal. Imaging is unreliable. Examination under anaesthesia and laparoscopy is performed at around 1 year. If palpable under anaesthesia, an inguinal orchidopexy is performed. At laparoscopy, a testis is absent if a blind-ending vas is seen. If the vas and vessels enter the inguinal canal, then the groin is explored. A canalicular testis may be amenable to an inguinal orchidopexy, or there may be a remnant to excise. If there is a viable intra-abdominal testis (***Figure 17.4***), a two-stage Fowler–Stephens orchidopexy is performed. In the first stage, testicular vessels are ligated, leaving the testis *in situ*, anticipating survival on the vessels accompanying the vas. Three

Anton Nuck, 1650–1692, Dutch anatomist and surgeon who described the peritoneal outpocketing neighbouring the round ligament of the uterus as it extends to the labia majora.
Peter H Lord, 1925–2017, Consultant General Surgeon, Wycombe General Hospital, High Wycombe, UK.
Mathieu Jaboulay, 1860–1913, Professor of Surgery in Lyon, France.
Sir Denis John Browne KCVO, 1892–1967, the first British surgeon to devote all his care to children.
Robert Fowler, b 1928, retired surgeon, Royal Children's Hospital Melbourne.
Frank Douglas Stephens, 1913–2011, paediatric surgeon who worked in Melbourne, Australia.

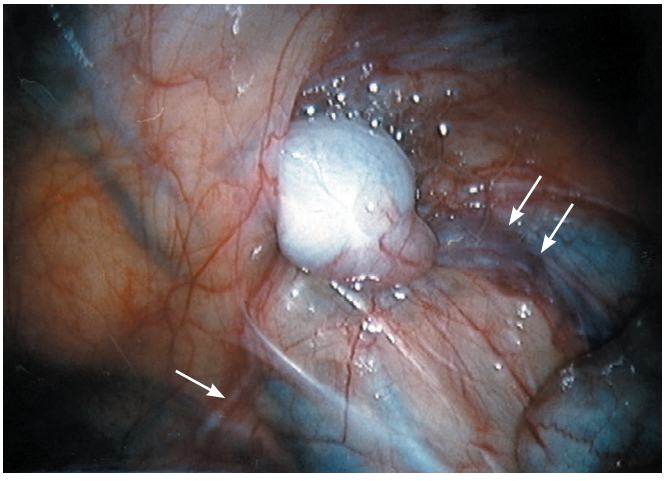

Figure 17.4 Laparoscopic view of a right-sided intra-abdominal testis visible at the internal ring. Vas (single arrow) and testicular vessels (double arrow).

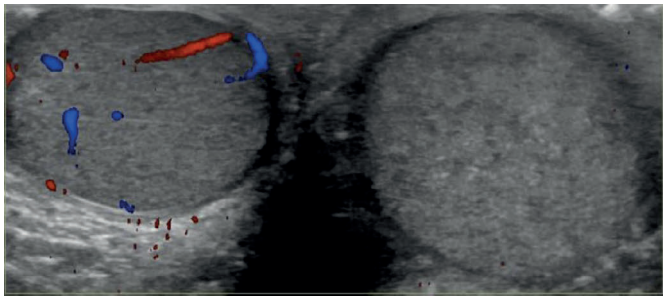

Figure 17.5 The red and blue colour on one testis shows normal blood flow whereas the contralateral testis has no blood supply, consistent with a torsion.

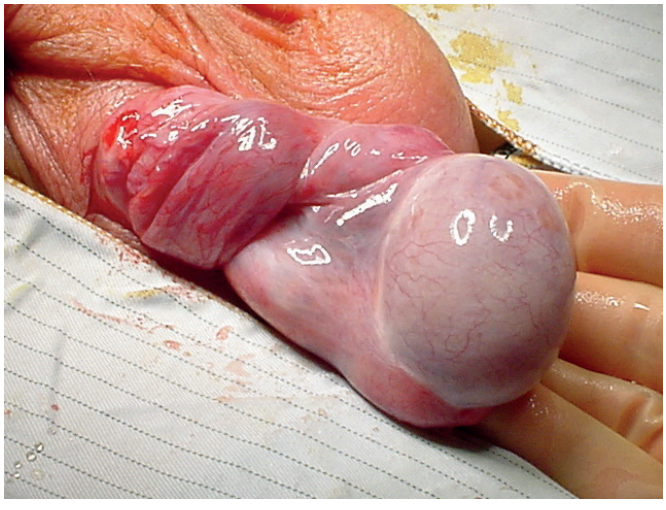

Figure 17.6 Torsion of the right testis with only modest vascular compromise in a boy with a history of intermittent pain.

months later a second operation is performed; if the testis has survived, it is brought into the scrotum.

ACUTE SCROTAL DISORDERS

Testicular torsion

Intravaginal (bell clapper) testicular torsion is well recognised in adolescents but may occur at any age. Abnormal posterior anchoring of the testis allows torsion within the tunica vaginalis. Torsion compromises blood flow, causing acute scrotal or abdominal/groin pain, nausea and vomiting. Tenderness, an absent cremasteric reflex and a high testis may be found on examination; oedema and erythema appear later. Sometimes there have been transient episodes (intermittent torsion). Doppler ultrasound may help (***Figure 17.5***). Exploration within 6–8 hours of the onset of symptoms improves the chances of testicular salvage.

At operation, testicular viability is assessed after derotation (***Figure 17.6***). Only gangrenous testes should be excised since some severely compromised testes survive, and those that then atrophy are not harmful. If salvageable, three-point fixation of both testes with non-absorbable sutures is performed or a dartos pouch is fashioned.

Extravaginal torsion is seen in newborns, with 70% occurring prenatally and 30% postnatally; emergency neonatal exploration remains controversial since salvage rates are low.

Torsion of the appendix testis and appendix epididymis

The appendix testis (hydatid of Morgagni) is a remnant of the Müllerian (paramesonephric) duct, whereas the appendix epididymis is a Wolffian (mesonephric) remnant. Both are small and pedunculated and are located on the upper testis or epididymis; they can twist and infarct (***Figure 17.7***). Appendage torsion occurs most commonly between 7 and 14 years. Mild to severe acute scrotal pain is present, usually without vomiting. On examination, a small area just above the testis may be tender; occasionally, a dark mass is visible, known as the blue-dot sign. A Doppler ultrasound can help exclude testicular torsion. Analgesia, and rest, may be sufficient, with exploration reserved for severe pain and equivocal cases.

Epididymo-orchitis

Bacterial or viral inflammation is occasionally found on exploration for suspected torsion. Epididymitis is seen before 6 months and is caused by infected urine travelling up the vas. Epididymo-orchitis (*Chlamydia trachomatis, Neisseria gonorrhoea* and *Escherichia coli*) is seen after puberty in sexually active boys presenting with acute testicular pain, dysuria, frequency, urethral discharge and fever. In addition, there may be scrotal

Giovanni Battista Morgagni, 1682–1771, Italian anatomist, considered the father of modern anatomical pathology.
Johannes Peter Müller, 1801–1858, German physiologist, comparative anatomist, ichthyologist and herpetologist.
Caspar Friedrich Wolff, 1733–1794, German physiologist and one of the founders of embryology.

Figure 17.7 Two torted and infarcted hydatids, one arising from the epididymis and one from the testis.

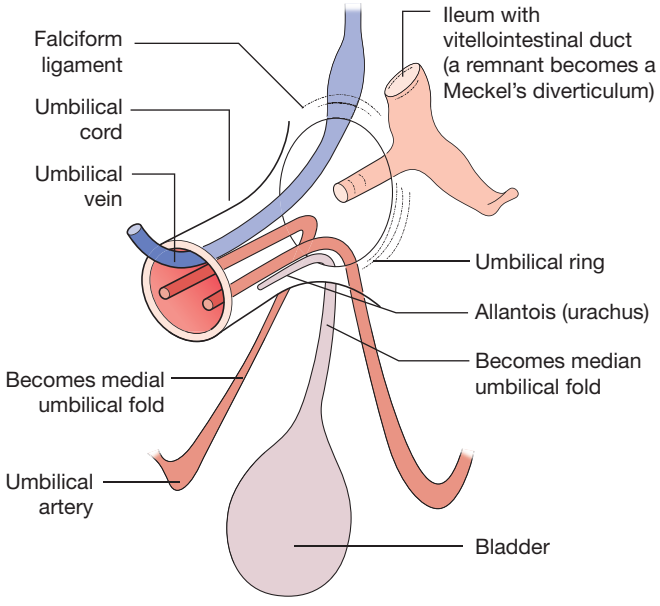

Figure 17.8 Structures at the umbilicus.

erythema and oedema with a normal cremasteric reflex. Pain may subside on elevation of the testis (Prehn's sign). Management includes rest, analgesia, antibiotics and re-evaluation if there is no improvement.

Idiopathic scrotal oedema

Typically, a 5- to 7-year-old boy presents with a swollen hemi-scrotum with erythema extending towards the anus and the groin. The testicle is scrotal and not tender, though the dartos and skin are swollen. Antihistamines may help.

MIDLINE HERNIAS

The embryonic umbilical ring encircles a defect in the ventral abdominal wall transmitting structures connecting the fetus to the placenta (***Figure 17.8***). Umbilical hernias are common following incomplete closure of the umbilical ring, though incarceration is rare. Most umbilical hernias resolve by 4 years. Supraumbilical hernias are defects in the linea alba just above the umbilical ring; these do not close but are still repaired around 4 years. Epigastric hernias are defects higher still that allow a small amount of preperitoneal fat to prolapse; they are repaired if symptomatic.

INFANTILE HYPERTROPHIC PYLORIC STENOSIS

Pyloric stenosis presents with non-bilious projectile vomiting starting between 2 and 6 weeks of age. Its presentation differs from infective causes of vomiting (e.g. meningitis, urinary tract infections [UTIs]) because of postprandial hunger. Once vomiting starts, its frequency and forcefulness increase daily, distinguishing it from gastro-oesophageal reflux (GOR), which waxes and wanes and starts shortly after birth. In the UK, pyloric stenosis affects 1:300 infants with a M:F ratio of 4:1. There is often a maternal family history.

If the presentation is early, clinical findings are unremarkable; if late, weight loss and dehydration requiring resuscitation predominate. The diagnosis is made on a test feed or on abdominal ultrasound showing a thickened and lengthened pylorus. In a test feed, gastric peristalsis is seen passing from left to right across the abdomen, and in a relaxed (feeding) baby, the pyloric 'tumour' is palpable as an 'olive' in the right upper quadrant. Feeds are discontinued, and the stomach is emptied with an 8–10Fr nasogastric tube. Loss of gastric acid causes a hypochloraemic, hypokalaemic alkalosis and correction may take 24–48 hours; 0.9% saline with 0.15% KCl in 5% glucose given at 6–7.5 mL/kg/h provides maintenance and corrects deficits in most babies. As the chloride deficit is replaced, the kidneys correct the pH.

Ramstedt's pyloromyotomy is performed laparoscopically or through a supraumbilical or right upper quadrant incision. A pyloric serosal incision is made, and the 'tumour' spread (***Figure 17.9***), leaving an intact submucosa from the duodenal fornix to gastric antrum. The incision must extend onto the stomach; short incisions cause an early recurrence. Postoperatively, intravenous fluids are continued until feeds are re-established within 24 hours. Early postoperative vomiting usually swiftly resolves, with GOR being more likely than an incomplete myotomy if it persists.

GOR is common and tends to resolve spontaneously with maturity. Persistent symptoms respond to thickened feeds and antireflux medication. Failure to thrive or respiratory problems demand investigation and, in some cases, laparoscopic fundoplication.

Douglas Prehn, 1901–1974, American urologist, Wisconsin, USA.
Wilhelm Conrad Ramstedt, 1867–1963, German surgeon credited with describing the pyloromyotomy.

Figure 17.9 Pyloromyotomy for infantile hypertrophic pyloric stenosis.

Figure 17.10 Ileocolic intussusception causing small bowel obstruction.

INTUSSUSCEPTION

Most intussusceptions occur between 2 months and 2 years. More than 80% are ileocolic (***Figure 17.10***), beginning proximal to the ileocaecal valve with an apex in the ascending or transverse colon. Strangulation can progress to gangrene and perforation. The lead point is commonly viral-induced hyperplasia in a Peyer's patch, but a few have a pathological lead such as a Meckel's diverticulum, duplication cyst or a small bowel lymphoma. Pathological leads are found more commonly in those over 2 years and in a recurrence.

A previously healthy infant presents with colicky pain, vomiting and drawing up their legs. Between episodes, they initially appear well. Later, they may pass a 'redcurrant jelly' stool. Signs include dehydration, abdominal distension and a palpable right upper quadrant mass.

A plain radiograph shows small bowel obstruction, a mass and a paucity of gas in the right iliac fossa. A concentric target sign is seen on an abdominal ultrasound. An air reduction enema is attempted after resuscitation with intravenous fluids, broad-spectrum antibiotics and nasogastric drainage (***Figure 17.11***). Success is recognised if air flows into the small bowel and symptoms and signs resolve. An air enema is contraindicated if there is peritonitis, perforation or shock. More than 70% are reducible non-operatively. Strangulation and pathological lead points are unlikely to reduce. Colonic perforation during pneumatic reduction is rare. Recurrence occurs in 5% after non-operative reduction. Operative reduction is performed open or laparoscopically. An irreducible intussusception or one complicated by infarction or a pathological lead point requires resection.

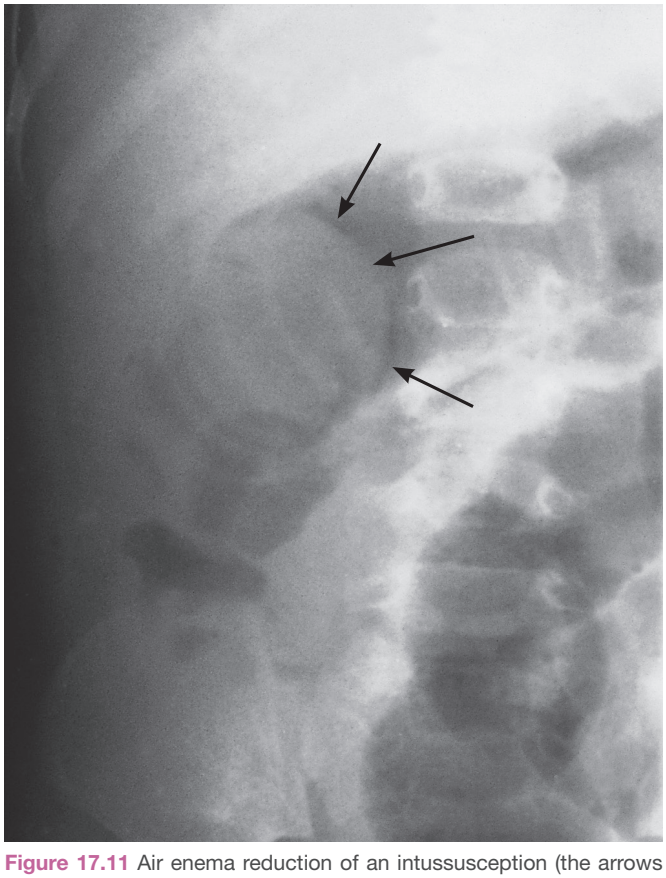

Figure 17.11 Air enema reduction of an intussusception (the arrows mark the soft tissue shadow of the intussusceptum).

ACUTE APPENDICITIS

In early appendicitis, there is a fever of 37.3–38.4°C, anorexia, a few vomits and central abdominal pain settling in the right iliac fossa. Persistent guarding in the right iliac fossa distinguishes it from self-resolving non-specific abdominal pain (NSAP). Investigations and scoring systems may help but neither replace regular clinical review. Treatment starts with intravenous fluids, analgesia and broad-spectrum antibiotics. Early appendicitis is managed laparoscopically, though some mild cases may resolve with antibiotics alone.

Johann Conrad Peyer, 1653–1712, Swiss anatomist.

Complicated appendicitis describes any of the following: perforation, abscess formation, a mass or generalised peritonitis. One pitfall is to diagnose gastroenteritis when there are loose stools, and another is to attribute pain on micturition and pyuria to a UTI; both can occur in pelvic appendicitis with a collection. Referred pain from right lower lobe pneumonia should be considered. Antibiotics given for any reason may mollify signs and delay or complicate a presentation. The diagnosis can be difficult in those under 5 years, with many presenting after a perforation. Before 5 years, the omentum is less well developed and inflammation less well contained. An appendix mass in an unobstructed child may respond to non-operative management with antibiotics. An interval appendicectomy can be considered 6 weeks later but is not mandated.

Non-specific abdominal pain

The clinical features of NSAP are similar to acute appendicitis, but the pain is poorly localised, not aggravated by movement and not accompanied by guarding. The site and severity of maximum tenderness vary on repeated examinations. Symptoms are typically self-limiting. The aetiology is obscure, but viral infections are hypothesised if there is lymphadenopathy. In some children, recurrent abdominal pain can be organic; in others, it is eventually attributed to an underlying psychosocial problem.

Rare causes of abdominal pain

Other causes of acute abdominal pain include Henoch–Schönlein purpura, sickle cell disease, primary peritonitis, acute pancreatitis, biliary colic, testicular torsion, gynaecological pathology (e.g. ovarian cysts and tumours, pelvic inflammatory disease, haematometrocolpos) and urinary stone disease. UTIs in children may be due to a urinary tract abnormality and may lead to renal scarring from ascending infection. Infection and obstruction are particularly hazardous; see ***Chapter 20***.

ANORECTAL PROBLEMS

Constipation

The passage of hard or infrequent stools may be secondary to an anal fissure, Hirschsprung's disease, an anorectal malformation, a neuropathic bowel, a mega-rectosigmoid or idiopathic constipation. A detailed history and examination of the abdomen, anus and spine identify most causes. A rectal biopsy may be needed to exclude late presenting Hirschsprung's disease. In the absence of surgical pathology, the child is best managed by a paediatrician.

Rectal prolapse

Rectal mucosal prolapse occurs in toddlers and is exacerbated by straining or squatting on defecation. It is typically intermittent and self-limiting. Underlying constipation should be treated. Rarely, it may be secondary to cystic fibrosis or spinal dysraphism. A rectal polyp can mimic a prolapse. Recurrent symptomatic prolapse may respond to injection sclerotherapy. Rare cases need laparoscopic rectopexy.

Meckel's diverticulum

A 4-year-old presenting with a haemoglobin level of 40 g/L will most likely have bled from an ulcer adjacent to a Meckel's diverticulum containing ectopic gastric mucosa (***Figure 17.12***). A technetium scan may demonstrate ectopic gastric mucosa (***Figure 17.13***). A Meckel's diverticulum may also be complicated by an obstructing band between the diverticulum and the umbilicus, diverticulitis, intussusception, intestinal volvulus or perforation.

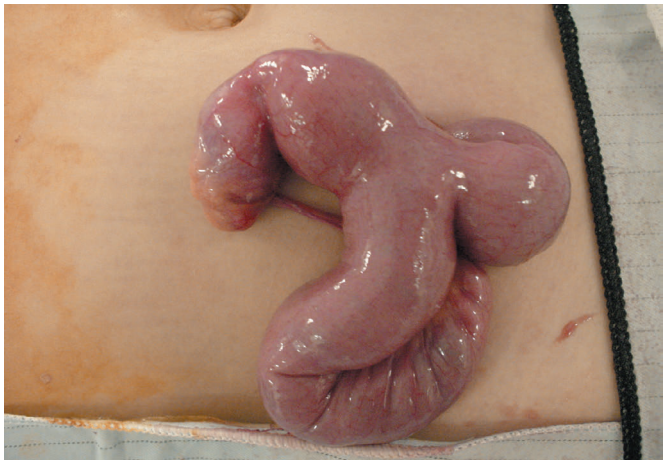

Figure 17.12 Meckel's diverticulum containing ectopic gastric mucosa.

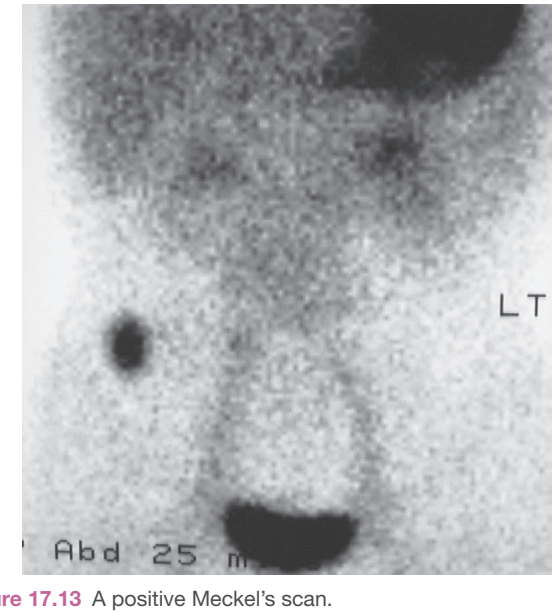

Figure 17.13 A positive Meckel's scan.

Eduard Heinrich Henoch, 1820–1910, Professor of Diseases of Children, Berlin, Germany, described this form of purpura in 1868.
Johann Lucas Schönlein, 1793–1864, Professor of Medicine, Berlin, Germany, published his description of this form of purpura in 1837.
Harald Hirschsprung, 1830–1916, physician, The Queen Louise Hospital for Children, Copenhagen, Denmark, described congenital megacolon in 1887.

Swallowed or inhaled foreign bodies

Coins and other foreign bodies are often swallowed and, if radio-opaque, are seen on a plain radiograph. Oesophageal objects are removed endoscopically under general anaesthesia. Oesophageal button batteries must be removed within hours as they can perforate into the trachea or aorta. Once beyond the cardia, most objects pass in a few days. Batteries in the stomach are removed urgently or followed closely with repeat radiographs. The need to remove sharp objects depends on their size, location and the age of the child. Ingested magnets can cause entero-enteric fistulae when they fix to one another in adjacent loops of bowel.

Inhaled foreign bodies cause sudden-onset coughing and stridor. If there is worsening dyspnoea or hypoxia in an infant they should be given back blows in a head-down position. Abdominal thrusts (Heimlich manoeuvre) are reserved for older children. A foreign body in a bronchus is suggested by a unilateral wheeze, decreased transmitted breath sounds and a hyperinflated lung on an expiratory chest radiograph. Rigid bronchoscopy with a ventilating bronchoscope facilitates removal.

GASTROSTOMY

A gastrostomy may be requested for nutritional support. Options include an open Stamm gastrostomy, a Ponsky–Gauderer percutaneous endoscopic gastrostomy (PEG) or a laparoscopic approach using a Seldinger technique. The Stamm gastrostomy employs two gastric purse-string sutures imbricated to fashion a tunnel. In the PEG technique, a gastroscope illuminates the stomach and abdominal wall, allowing identification of a site through which a needle and wire are passed into the stomach and extracted orally. A gastrostomy tube is then drawn into place. In the Seldinger technique, the stomach is punctured percutaneously with a needle through which a guidewire is advanced, and the needle is then withdrawn. A series of dilators are passed over the guidewire and finally the gastrostomy tube; the guidewire is then withdrawn.

PAEDIATRIC SURGICAL ONCOLOGY

Neuroblastoma and nephroblastoma are two solid abdominal tumours.

Neuroblastomas arise in the adrenal medulla or sympathetic ganglia and present with an abdominal or paravertebral mass. They metastasise to lymph nodes, bone and liver, raising urinary catecholamine levels. Small, localised tumours are excised. Advanced tumours are excised after chemotherapy. Survival exceeds 90% for small, localised tumours but is less than 50% for advanced tumours.

Wilms' tumour (nephroblastoma) is a malignant renal tumour derived from embryonal cells and typically presenting with an abdominal mass between 1 and 4 years. A mutation in the Wilms' tumour suppressor gene (*WT1*) causes some cases. The tumour can extend into the renal vein and vena cava and metastasises to lymph nodes and lungs. Treatment is with chemotherapy and surgery. Survival depends on tumour spread, completeness of excision and histological appearance but exceeds 70% even with advanced tumours.

Henry Judah Heimlich, 1920–2016, thoracic surgeon, Xavier University, Cincinnati, OH, USA.
Martin Stamm, 1847–1918, American gastric surgeon, educated in Germany.
Jeffrey Ponsky, contemporary, endoscopist, Rainbow Babies & Children's Hospital, University Hospitals of Cleveland, Cleveland, OH, USA.
Michael WL Gauderer, contemporary, paediatric surgeon, Greenville, SC, USA.
Sven Ivar Seldinger, 1921–1998, Swedish radiologist, introduced the procedure in 1953.
Carl Max Wilhelm Wilms, 1867–1918, German pathologist and surgeon, died of diphtheria after operating on the larynx of a French prisoner of war.